Received: 4 September 2019 | Revised: 12 November 2019 | Accepted: 10 December 2019

DOI: 10.1111/jocd.13285

ORIGINAL CONTRIBUTION

JCD Journal of Cosmetic Dermatology WILEY

Retrospective photographic review of nontattoo indications treated by picosecond laser

Joseph N. Mehrabi BSc[1] | Or Friedman MD[1,2] | Firas Al-Niaimi MD[3] | Ofir Artzi MD[1,2,4]

[1]Sackler Faculty of Medicine, Tel-Aviv University, Tel-Aviv, Israel

[2]Dr.Artzi and Associates – Treatment and Research Center

[3]Department of Dermatology, Tel-Aviv University, Tel-Aviv, Israel

[4]Department of Dermatology and Venereology, Tel-Aviv Sourasky Medical Center, Tel-Aviv, Israel

Correspondence
Ofir Artzi, Department of Dermatology, Tel Aviv Sourasky Medical Center, 6 Weizman Street, Tel Aviv 642906, Israel.
Email: ofira@tlvmc.gov.il

Abstract

Background: Picosecond (PS) lasers were approved by the US FDA in 2012 after being shown to remove tattoos with more success and fewer treatments compared with traditional methods. PS lasers were shown to be versatile, indicated for the treatment of lentigines, café-au-lait macules (CALMs), and acne scars and skin rejuvenation.

Objective: We report our experience treating our patients for different indications using a PS laser.

Methods: We performed a retrospective chart and photographic review of all patients seen between 2016 and 2018 that were treated in our centers with a PS laser for nontattoo indications. Clinical outcomes were evaluated using side-by-side comparisons of the clinical photographs by two blinded, independent physicians using a visual analog scale consisting of six levels of treatment response.

Results: A total of 233 patients were studied. Most sought treatment for solar lentigo (27%) and skin rejuvenation (14%). Epidermal nevi exhibited the greatest improvement with treatment, while acne scarring demonstrated the least. Only 24% of patients experienced noteworthy, transient adverse effects.

Conclusion: Picosecond lasers were efficacious and safe for a variety of indications. They were effective in treating epidermal nevi and pigmented lesions, such as Lentigines and CALMs.

KEYWORDS

aesthetic improvement, epidermal nevus, laser treatment, picosecond laser, solar lentigines

1 | INTRODUCTION

Dermatology is a rapidly advancing field with many technologies added to the expanding armamentarium of the physician, particularly in the cosmetic sector of the specialty. Patients of all age groups and backgrounds seek treatment for skin conditions; these range from young adults with acne and acne scarring to the elderly requiring skin rejuvenation. energy-based devices (EBDs) are increasingly frequently used for the treatment of different aesthetic dermatological problems. Every technology offers a different mechanism of action, recovery timescale, and adverse effects. New technologies are becoming costlier, and this may have implications on the ratio of service to cost-effectiveness. A well-tolerated EBD procedure that can effectively treat different skin types and multiple skin conditions with minimal adverse effects and shortened downtime might be more economically attractive due to its versatility and favorability among patients and treating physicians alike.

Picosecond (PS) lasers were approved by the US FDA in 2012 for the removal of tattoos.[1] The iconic feature of the PS laser is that its pulse duration is less than a nanosecond, achieving a photoacoustic effect and limiting the amount of thermal damage delivered to surrounding tissue.[2,3] Aside from tattoo removal, PS

TABLE 1 Subject demographics, clinical characteristics

	Subject demographics													
	No. of subjects			Location of lesion				Fitzpatrick skin type						
Lesion	Female	Male	Mean age (SD)	Face	Trunk	Upper extremity	Lower extremity	I	II	III	IV	V	VI	Total
Nevus of Ota	3	1	36 (7.5)	4	0	0	0	0	0	2	2	0	0	4
Venous stasis HP	3	1	62.3 (4.9)	0	0	0	4	0	3	1	0	0	0	4
Acquired benign nevi	3	2	36.8 (12.5)	3	0	2	0	0	1	2	1	1	0	5
PIH	6	1	37.9 (6.9)	4	2	1	0	0	1	4	2	0	0	7
Epidermal nevus	8	4	24.0 (9.1)	7	4	1	0	2	7	1	2	0	0	12
Periorbital darkening	11	2	56.8 (7.8)	13	0	0	0	0	0	3	7	3	0	13
CALM's	10	4	23.3 (6.6)	7	4	1	2	1	6	5	2	0	0	14
Hyperpigmented scar	8	7	33.2 (14.0)	9	2	4	0	0	4	4	5	1	1	15
Striae	14	2	42.8 (8.8)	0	12	0	4	0	8	5	3	0	0	16
Acne Scars	18	3	31.1 (8.5)	21	0	0	0	0	3	7	9	2	0	21
Melasma	24	2	36.3 (6.6)	26	0	0	0	0	5	9	10	2	0	26
Skin rejuvenation	27	5	59.5 (10.6)	22	10	0	0	0	22	9	1	0	0	32
Solar lentigo	60	4	54.7 (12.4)	48	8	8	0	0	44	16	4	0	0	64
Total	195	38	44.3 (16)	164	42	17	10	3	104	68	48	9	1	233

lasers have been shown to be versatile and valuable in the treatment of various conditions such as lentigines, café-au-lait macules (CALMs), nevus of Ota, acne scarring, and skin rejuvenation.[4-7] In this article, we report our experience treating a wide range of indications using a PS laser.

2 | METHODS

We performed a retrospective chart and photographic review of all patients seen between 2016 and 2018 that were treated in two centers with a PS laser for different indications excluding tattoo removal. Information from the patient's medical record was extracted, which included the gender, the age of patient at time of treatment, condition being treated, anatomic location of the lesion, number of treatments, interval between each treatment, PS laser handpiece chosen to treat the lesion, and, where applicable, the posttreatment topical applications given for each indication. Lesions located on the chest, abdomen, and back were consolidated to lesions located on the trunk; lesions on the shoulder, arm, and hand were consolidated to the upper extremity; lesions on the buttocks, thigh, and legs were consolidated to the lower extremity; and lesions on the forehead, cheeks, and chin were consolidated to the face.

The PS laser used was the Picoway laser (Candela) with both the nonfractional "zoom" handpiece and the fractional "resolve" handpiece. The choice of the handpiece was based on the indicated lesion and/or physician experience or preference and consisted of the aforementioned handpieces in both 532 and 1064 nm wavelengths. Protective eyewear was utilized during treatments. Laser settings varied for each patient and lesion being treated and were based on the patients' individual levels of comfort and tolerance, clinical end point, published evidence, and/or physician experience or preference. Emla (lidocaine 2.5%, prilocaine 2.5%) cream was applied to the areas of treatment 1 hour before the procedure. Postprocedure care included topical Biafin (trolamine) self-applied 3-4 times per day for 1 week and the use for 3 months of broad-spectrum sunscreen with an SPF of 50 for patients treated on only sun-exposed areas.

The patients were photographed using a standardized high-definition digital camera at baseline before treatment and at variable intervals ranging between 3 and 9 months postfinal treatment. Clinical outcomes were evaluated using side-by-side comparisons of the clinical photographs by two blinded, independent physicians using a visual analog scale consisting of six levels of treatment response according to percentage of improvement or pigmentary lightening and correspondence to normal skin appearance. Grade 0 corresponds to 0%-5% change; grade 1, 6%-24% improvement; grade 2, 25%-49% improvement; grade 3, 50%-74% improvement; grade 4, 75%-99% improvement; and grade 5, 100% improvement or complete clearance. Patients were also asked to rate the improvement following treatment on the same scale 1-3 months after the final treatment. This chosen scale enables seamless comparison of treatment results of different skin lesions.

As a standard of care in our clinics, a phone questionnaire was performed 7-10 days after each treatment to collect information

TABLE 2 Parameters of treatment

Lesion	Wavelength	Fluence estimate	Passes	Clinical end point	No. of Tx. (SD)	Interval length in weeks (SD)
Nevus of Ota	Zoom 1064 nm	4-5 mm, 1.8-2.8 J/cm^2	2	Erythema (mild purpura)	2.5 (0.6)	6.3 (0.5)
Venous stasis HP	Resolve 1064 nm	1.5- 2 J/cm^2	4-5	Erythema	6.0 (0.8)	3.5 (0.6)
Acquired benign Nevi	Zoom 532 nm	4-5 mm, 0.8-1.6 J/cm^2	2	Frosting	1.6 (0.5)	5.8 (0.4)
PIH	Resolve 1064 nm	1.5-2.3 J/cm^2	2	Erythema	2.3 (0.8)	7.6 (1.7)
Epidermal nevus	Zoom 532 nm	3 mm, 1.8-2 J/cm^2	3-4	Greying/frosting	4.3 (1.2)	6.7 (0.9)
Periorbital darkening	Zoom 1064 nm	8-9 mm, 0.5-0.9 J/cm^2	1-2	Erythema	3.7 (0.6)	5.6 (0.9)
CALM's	Zoom 532 nm	4-5 mm, 0.8-1.6 J/cm^2	1-2	Frosting	2.5 (1.2)	5.3 (1.3)
Hyperpigmented scar	Resolve 1064 nm	1.5-2.3 J/cm^2	2-3	Erythema and edema	4.2 (1.2)	4.5 (0.8)
Striae	Resolve 1064 nm	1.9-2.5 J/cm^2	4-5	Erythema (mild purpura)	6.4 (1.5)	4.3 (0.8)
Acne scars	Resolve 1064 nm	1.9-2.5 J/cm^2	3-4	Erythema and edema	5.4 (0.7)	4.0 (0.6)
Melasma	Combination Treatment[a]	Low settings	2-4	Erythema	3.3 (0.5)	5.7 (0.8)
Skin rejuvenation	Resolve 1064 nm	1.5-2.1 J/cm^2	2-3	Erythema and edema	4.8 (0.8)	3.3 (0.4)
Solar lentigo	Zoom 532 nm	3-4 mm, 0.5-1.2 J/cm2	1-2	Darkening/greying/ frosting	3.6 (0.8)	4.0 (0.9)
Total					4.0 (1.4)	4.6 (1.4)

[a]Combination treatment: Resolve 1064 nm + (Zoom 1064 nm or Zoom 532 nm).

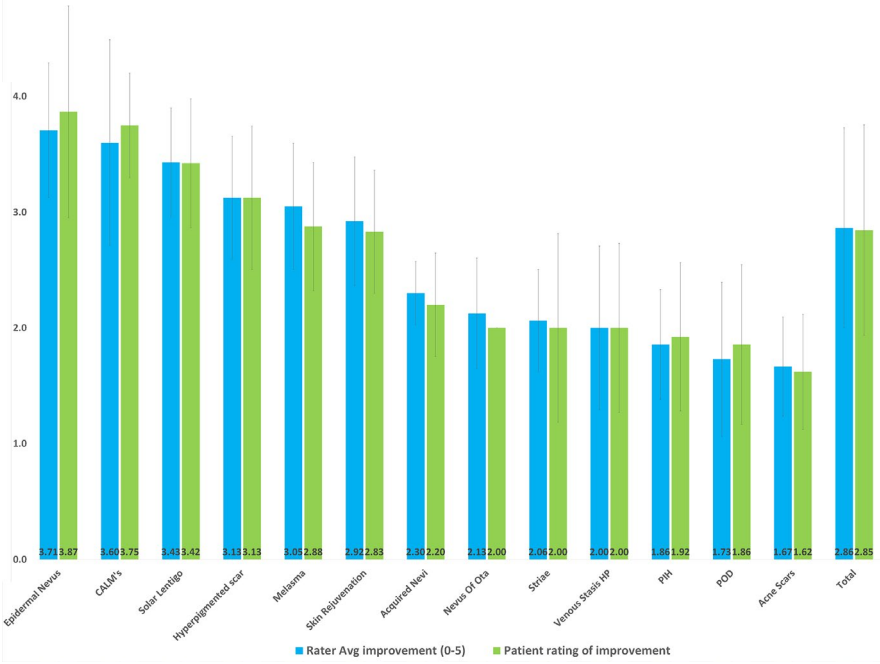

FIGURE 1 The improvements of different indications following PS laser treatment as evaluated by the blinded evaluators and patients [Color figure can be viewed at wileyonlinelibrary.com]

about adverse effects, downtime, tolerance of treatment, and patient satisfaction following the treatment. The patients' pain tolerance was rated on a scale of 1-10; 1 = no pain, 10 = very painful.

3 | RESULTS

The clinical characteristics of the subjects are summarized in Table 1. A total of 233 patients, 195 females and 38 males, were studied. The mean age at the time of laser treatment was 44.3 years (range 8-87 years); however, the mean ages of subjects varied with skin condition to be treated. The youngest patients were treated for CALMs (average age = 23.3) and the oldest for venous stasis hyperpigmentation (average age = 62.3). Lesions on the face were the most treated (71%) reflecting obvious cosmetic desires while lower extremity lesions were the least targeted (2%). All Fitzpatrick (FP) skin types were treated; however, the most common FP skin types were FP II (45%), FP III (29%), and FP IV (21%), reflecting the demographics of the treated population.

Most treatments performed were for solar lentigines (27%) and skin rejuvenation (14%). A summary of the treatment protocol for each lesion is demonstrated in Table 2. The most widely used PS laser handpiece used was the Resolve 1064 nm (7 of the 13 indications) and the Zoom 532 nm handpiece was most commonly used, treating 98 patients, the majority of whom required treatment for solar lentigines. The overall average number of treatments for all lesions was 3.9. Striae, venous stasis hyperpigmentation (HP), and acne scars required the most treatments with an average of 6.4, 6.0, and 5.4, respectively, and acquired benign nevi, nevus of Ota, and CALMs required the least number of treatments with an average of 1.6, 2.5, and 2.5, respectively. While every type of skin lesion treated with a PS laser exhibited improvement, there was variability observed in the response to treatment. The greatest improvement was exhibited in the treatment of epidermal nevi, with the Zoom 532 nm handpiece, and acne scarring demonstrated the lowest degree of improvement, with the Resolve 1064 nm handpiece. Patient opinions differed slightly from those of the objective raters. Figure 1 summarizes these results. As shown in Table 3, treatment with the PS lasers was well tolerated, and the recovery time after each treatment was on average quite low except for the patients treated for epidermal nevi with the Zoom 532 nm. Adverse effects of the treatment of each skin condition are summarized in Table 4; of 233 patients, only 56 (24%) experienced

TABLE 3 Subjective evaluation

Lesion	Pain (SD) [1-10]	Downtime (SD) [d]
Melasma	2.4 (0.5)	4.03 (0.8)
Venous stasis HP	2.75 (0.5)	2.25 (0.5)
PIH	2.43 (0.5)	4.86 (0.7)
Hyperpigmented scar	2.25 (0.4)	2.88 (0.7)
Striae	2.56 (0.6)	2.56 (0.5)
Acne scars	3.76 (0.8)	3.14 (1.0)
Skin rejuvenation	3.13 (0.7)	4.69 (1.1)
POD	4.61 (0.8)	4.38 (1.0)
Nevus of Ota	4.5 (0.6)	5.75 (0.5)
Acquired nevus	4.4 (0.5)	4.4 (0.5)
Epidermal nevus	4.92 (0.7)	9.75 (2.4)
CALM's	4.67 (0.5)	7.47 (1.7)
Solar lentigo	3 (0.8)	3.84 (1.0)
Total	3.25 (1.0)	4.37 (2.0)

TABLE 4 Adverse effects (AE) by handpiece

	Zoom 532 nm	Zoom 1064 nm	Resolve 1064 nm	Combination treatment[a]	Total
Hyperpigmentation	4	3	5	1	13
Hypopigmentation	4	1	0	2	7
Blistering	2	1	0	1	4
Pustular eruption	3	0	15	1	19
Purpura	2	0	7	0	9
Persistent erythema	0	1	2	1	4
Total AE	15	6	29	6	56
Total treated	98	15	94	26	233
AE index (%)[b]	15.3	40.0	30.9	23.1	24.0

[a]Combination Treatment: Resolve 1064 nm + (Zoom 1064 nm or Zoom 532 nm).
[b]AE index: Total AE over Total Treated

TABLE 5 The use of PS lasers in prior studies

Reference (year)	Indication	Device (wavelength, nm)	No. of Tx	Interval (wk)
Brauer et al (2015)[6]	Acne scarring	Cynosure (755 nm)	6	4-8
Huang et al (2019)[41]	Acne scarring	PicoSure (755 nm)	2-12	2-6
Dierickx et al (2018)[42]	Acne scarring	PicoSure (755 nm)	5	4
Artzi et al (2017)[4]	CALM	Picoway (532 nm)	1-4	4-8
Levi et al (2018)[11]	Epidermal nevi	Picoway (532 nm)	6	8-10
Koren et al (2019)[15]	Hyperpigmented scars	Picoway (1064 nm)	3-5	3-6
Lee et al (2018)[18]	Melasma	PicoSure (755 nm)	4	4
Chalermchai (2018)[19]	Melasma	Picoway (1064 nm)	3	4
Choi et al (2017)[20]	Melasma	PICO41 (1064 nm)	5	1
Peng et al (2018)[31]	Nevus of Ota	Alexandrite laser (755 nm)	1-5	
Yu et al (2018)[29]	Nevus of Ota	PicoSure (755 nm)	3	24
Wong et al (2018)[30]	Nevus of Ota	LIGHTen (1064/532 nm)	6-9	4-12
Lee et al (2017)[34]	PIH	Cynosure (755 nm)	6-14	2
Khetarpal et al (2016)[7]	Skin rejuvenation	PicoSure (755 nm)	4	3
Weiss et al (2017)[21]	Skin rejuvenation	PicoSure (755 nm)	4	4
Wat et al (2019)[43]	Skin rejuvenation	PicoSure (755 nm)	4	6
Diericks et al (2018)[42]	Skin rejuvenation	PicoSure (755 nm)	5	4
Vachiramon et al (2018)[14]	Solar lentigines	Picoway (532 nm)	1	
Scarcella et al (2018)[12]	Solar lentigines	Picoway (532 nm)	2	4
Negishi et al (2018)[13]	Solar lentigines	Enlighten™ (532 and 1064 nm)	3	4-6
Zaleski-Larson et al (2018)[32]	Striae	Fractional Nd:YAG (1064/532 nm)	3	3

noteworthy, yet transient, adverse effects of the treatment with the PS laser.

4 | DISCUSSION

Picosecond lasers can generate and deliver a pulse of high energy in less than a nanosecond.[8] They were approved for use in tattoo removal in 2012, and the scientific community has been actively discovering its broad applications beyond tattoos, which include pigment clearance and tissue remodeling. A high energy pulse delivered in a very short time frame creates photoacoustic effects without the delivery and dispersion of harsh, adverse, and thermal effects.[9]

As demonstrated in Table 5, prior studies have evaluated the efficacy and safety of PS lasers in nontattoo indications. The purpose of this study was to report our two-center experience of treating the same nontattoo indications over a 3-year period, in order to shed light on the costs and benefits, efficacy and shortcomings, and utility and suitability of the PS laser for each of the aforementioned indications.

4.1 | Epidermal nevi

CO_2 and Er:YAG lasers have been reported to be beneficial in the treatment of epidermal nevi. However, these lasers produced undesired side effects, such as postinflammatory hyperpigmentation (PIH), postoperative erythema, and atrophic scarring.[10] PS lasers might produce subdermal blistering, elegantly separating the epidermal lesion from the dermis with less thermal injury and a lower tendency to cause scarring.[11] This might explain the strong objective improvement (Figure 2 = B&A pic) and subjective satisfaction with minimal adverse effects except for a long downtime and moderate pain.

4.2 | CALM

PS lasers have been shown to be quite superior over other methods, including various Q-switched (QS), Er:YAG, copper vapor, and pulse dye lasers.[4] QS lasers were shown to exhibit dyspigmentation and even scarring, with variable recurrence. The PS laser proved to be quite effective and safe at clearing CALMs (Figure 3 = B&A pic), demonstrating comparable or better efficacy compared with other laser modalities. Still, there is no advantage over QS lasers in terms of preventing recurrence and the average required number of treatments to achieve clearance.

4.3 | Solar lentigines

Our study demonstrated high efficacy of PS laser treatment for the indication of solar lentigo. However, this specific indication with PS lasers should be compared directly against that of other nonlaser devices (eg, intense pulsed light) or other laser modalities especially the QS lasers. Solar lentigo treatment with a PS laser is not necessarily superior to QS lasers, which are more readily available and cost-effective.[12-14] Speed of clearance, number of treatment sessions, and the associated low side-effects profile with the PS lasers might, however, be an added advantage, especially in dark or Asian skin types.

4.4 | Hyperpigmented scar

Our experience with the PS laser for treatment of hyperpigmented scarring is promising, exhibiting satisfactory results (Figure 4 = B&A pic) with a low side effect and pain profile and minimal downtime, similar to our past experience.[15] Nevertheless, our experience does not seem to have differed much from prior treatments using a fractional nonablative laser.[16] Considering the cost of a fractional nonablative laser compared to that of a novel PS laser, the practicality of treating hyperpigmented scars with a PS laser over other options may require more thorough and direct investigation.

4.5 | Melasma

Melasma is a difficult condition to treat, and PS lasers seem to be a good treatment option based on the literature and our own experience, but not with unqualified success. Q-switched laser toning, a technique used for the treatment of melasma, involves using low fluence, an enlarged spot size, and multiple passes. The nature of the disease—partial remission and high recurrence rate—still rendered laser toning imperfect for the treatment of melasma in one study.[17] In a recent prior study, PS lasers were shown to be superior to QS lasers in direct comparison for the treatment of melasma on the face.[18] In our centers, melasma treatment with the PS laser showed moderate improvement (Figure 5 = B&A pic) and minimal side effects, consistent with prior studies having similar success while others had mixed success.[18-20] With that being said, the main issue of melasma is its high recurrence rate, which is independent of the technology used. More studies of longer follow-up periods are mandatory in order to really compare between technologies and their long-term efficacy.

4.6 | Skin rejuvenation

Skin rejuvenation using the PS laser in our study was quite satisfactory, and in prior studies, significant satisfactory improvement was discerned.[7,21] Skin rejuvenation can be achieved by many energy-based strategies [22-24] at much lower price points. However, direct comparison of the PS laser to these technologies for utility in skin rejuvenation is warranted to determine its true advantage.

4.7 | Acquired nevi

Average improvement of acquired nevi was modest for each patient but with little downtime, few side effects, and little pain. QS, Er:YAG, alexandrite, and Nd:YAG lasers have all exhibited mixed success with few side effects, with some being more successful than others.[25-28] Without real direct comparison, it is difficult to draw any specific conclusions as to which might be superior. PS lasers would be recommended over the aforementioned modalities if the results we experienced were more than adequate; however, direct comparison between the modalities is warranted in order to truly discern the best energy-based solution, if there is one, for the treatment of acquired melanocytic nevi. The PS laser commonly exhibits a lower side effect profile than other modalities for many indications, but for this acquired nevi, no real advantage can be seen on this front.

4.8 | Nevus of Ota

PS lasers showed superiority over the Q-switched laser in treatment of nevus of Ota in past studies, and our experience

FIGURE 2 Representative patient with epidermal nevus before and after PS laser treatment. To note that the bulkier lesions were removed with fully ablative Co2 laser [Color figure can be viewed at wileyonlinelibrary.com]

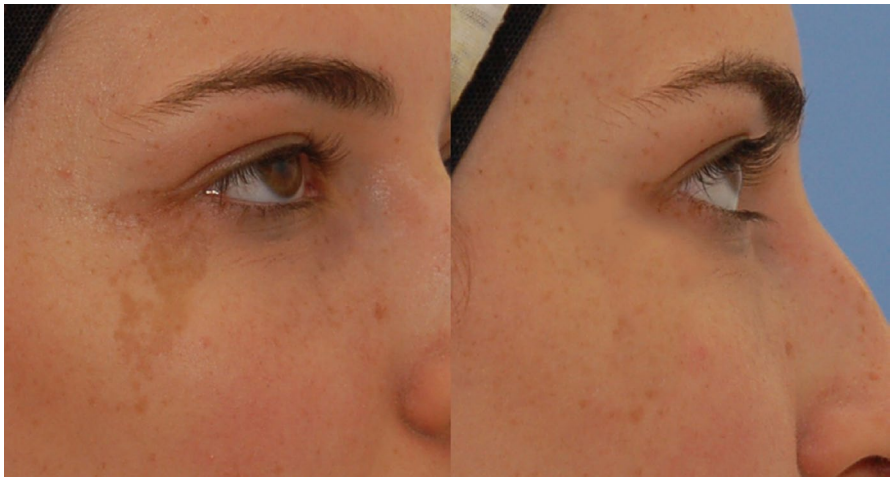

FIGURE 3 Representative patient with CALM before and after PS laser treatment [Color figure can be viewed at wileyonlinelibrary.com]

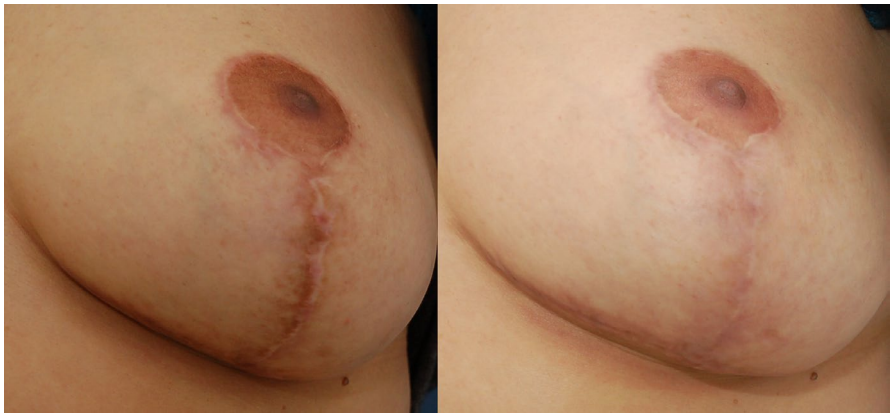

FIGURE 4 Representative patient with hyperpigmented scar before and after PS laser treatment [Color figure can be viewed at wileyonlinelibrary.com]

has shown similar efficacy and superiority over Q-switched lasers with fewer sessions and less side effects.[29] Moderate to excellent results were seen in our study and in those prior.[30,31]

4.9 | Striae

Striae can only be improved by multiple treatments. Different studies advocate the use of different modalities for this indication and

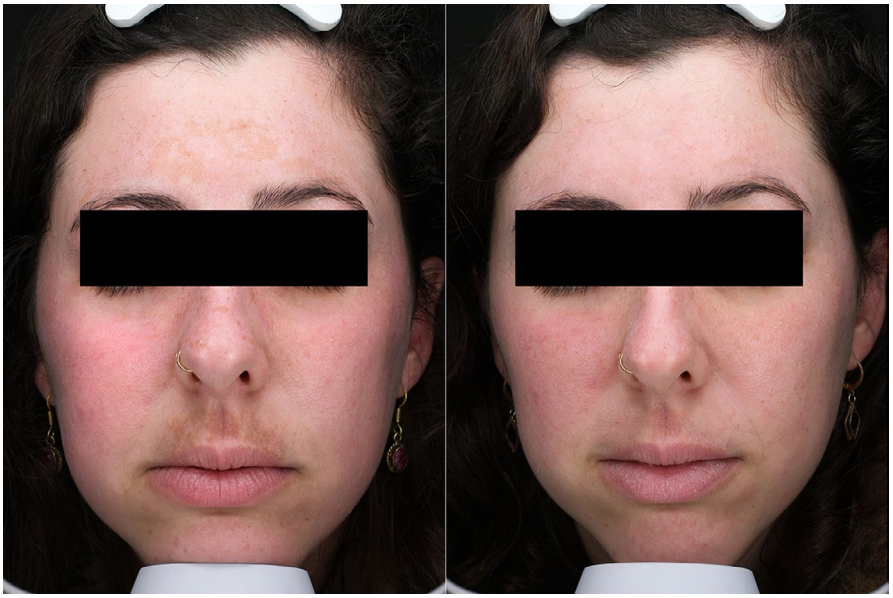

FIGURE 5 Representative patient with Melasma before and after PS laser treatment. To note that a partial recurrence was demonstrated 6 mo posttreatment [Color figure can be viewed at wileyonlinelibrary.com]

some even compare the rate of improvement. One prior study compared the efficacy of PS lasers to that of Er-glass in the treatment of striae and demonstrated that PS lasers were just as effective in treating striae as Er-glass but with less pain.[32] In our centers, PS lasers will not be chosen as first line priority for striae but we do acknowledge that the resolve fractional handpiece provided the patients with moderate results and was well tolerated by patients with satisfactory results.

4.10 | Venous stasis hyperpigmentation

Our study demonstrated moderate improvement of venous stasis HP whereas one prior study demonstrated it was quite successful.[33] Hemosiderin depth and density may contribute to the variability. Furthermore, different wavelengths were used in treating our patients than those used in the published studies which could play a role here. We chose to use the resolve fractional handpiece in this condition given our positive experience with the treatment of melasma and PIH with this handpiece compared to the nonfractional zoom handpiece.

4.11 | Postinflammatory hyperpigmentation

Fair to good improvement was seen in treatment of PIH with the PS laser in a prior case study, whereas we demonstrated some improvement compared with the treatment of other lesions, albeit below what we had expected.[34]

4.12 | Periorbital darkening

Our experience with the PS laser for periorbital darkening was positive, yielding satisfactory results, but other options from prior studies have generated seemingly better results. Prior studies examining

FIGURE 6 Representative patient with acne scars before and after PS laser treatment [Color figure can be viewed at wileyonlinelibrary.com]

QS laser treatment reported either similar or superior results with negligible downtime.[35,36] Long-pulsed Nd:YAG treatment was reported to be quite optimal, exhibiting complete clearance, almost no adverse effects, and high patient satisfaction.[37] Er-fiber is also a viable option offering similar capabilities.[38,39]

4.13 | Acne scarring

In prior studies using different PS lasers, acne scarring responded well, especially with the use of a diffractive lens array handpiece in up to six treatments. [6,40,41] However, only modest improvement was observed in our centers (Figure 6 = B&A pic). This can be explained by the use of different settings, different patient expectations, a difference in wavelength, and different device manufacturer. However, this indication should be called into question when tailoring treatment combinations for acne scars.

In this report, we attempt to demonstrate our experience with the PS laser for treatment of a multitude of benign skin lesions. The PS laser has been shown to be superior to current devices in terms of downtime, aggressiveness, and efficacy for many indications. From our experience, it is the among the optimal devices for treating epidermal nevi and CALMs and tattoo removal; for some indications, it may exhibit only a marginal advantage in efficacy and lack of adverse effects compared with current devices on the market; and for others, it may be similar or inferior to the current devices against which it is compared. Any adverse effects experienced by our patients were mild, transient, and highlighted in Table 4. Our low threshold for accounting for adverse events would explain the relatively high rates for the 1064 nm handpieces. The advantages of treatment with a PS laser must be weighed against the relatively lofty price and maintenance cost of the device.

Our report does have its limitations. Experience with the PS laser may differ between patient demographics, between physicians, between handpieces, and between indications; our report is purely based on our experience treating in two centers, and it may differ from the experience of PS laser application to other demographics in other centers in other parts of the world. The results of our study are compared with the results and experiences of using the PS laser or other energy-based devices that are reported in other studies. The bias that may exist in such studies as well as their own shortcomings serves as another limitation to our analysis and comparisons of the PS lasers to other devices. Patients were recruited in Israel and England, resulting in a select patient population, and the small number of patients with nevus of Ota, venous stasis HP, and acquired benign nevi limits our analysis on the efficacy of the PS laser for these conditions.

5 | CONCLUSION

This is the first photographic review of the application of PS laser for different nontattoo indications. The PS laser was shown to be a versatile device. However, for certain indications there are better or equivalent devices that may be more cost-effective. The pursuit of a PS laser should be weighed based on the prospective return on investment of the investing physician.

CONFLICT OF INTEREST

None declared.

ORCID

Joseph N. Mehrabi https://orcid.org/0000-0002-2212-7075
Or Friedman https://orcid.org/0000-0002-4362-7909
Firas Al-Niaimi https://orcid.org/0000-0002-0684-4322

REFERENCES

1. Graber E, Iyengar V, Rohrer T, Arndt K. Laser treatment of tattoos and pigmented lesions. In: *Surgery of the Skin: Procedural Dermatology*, 2nd edn. China: Mosby; 2010:537-548.
2. Liu T, Wang J, Petrov GI, Yakovlev VV, Zhang HF. Photoacoustic generation by multiple picosecond pulse excitation. *Med Phys*. 2010;37(4):1518-1521.
3. Forbat E, Al-Niaimi F. The use of picosecond lasers beyond tattoos. *J Cosmet Laser Ther*. 2016;18(6):345-347.
4. Artzi O, Mehrabi JN, Koren A, Niv R, Lapidoth M, Levi A. Picosecond 532-nm neodymium-doped yttrium aluminium garnet laser—a novel and promising modality for the treatment of café-au-lait macules. *Lasers Med Sci*. 2018;33(4):693-697.
5. Chesnut C, Diehl J, Lask G. Treatment of nevus of Ota with a picosecond 755-nm alexandrite laser. *Dermatol Surg*. 2015;41(4):508-510.
6. Brauer JA, Kazlouskaya V, Alabdulrazzaq H, et al. Use of a picosecond pulse duration laser with specialized optic for treatment of facial acne scarring. *JAMA Dermatol*. 2015;151(3):278-284.
7. Khetarpal S, Desai S, Kruter L, et al. Picosecond laser with specialized optic for facial rejuvenation using a compressed treatment interval. *Lasers Surg Med*. 2016;48(8):723-726.
8. Freedman JR, Kaufman J, Metelitsa AI, Green JB. Picosecond lasers: the next generation of short-pulsed lasers. *Semin Cutan Med Surg*. 2014;33(4):164-168.
9. Ross EV, Naseef G, Lin C, et al. Comparison of responses of tattoos to picosecond and nanosecond q-switched neodymium:yAg lasers. *Arch Dermatol*. 1998;134(2):167-171.
10. Osman MAR, Kassab AN. Carbon dioxide laser versus erbium: YAG laser in treatment of epidermal verrucous nevus: a comparative randomized clinical study. *J Dermatol Treat*. 2017;28(5):452-457.
11. Levi A, Amitai DB, Mimouni D, Leshem YA, Arzi O, Lapidoth M. Picosecond 532-nm neodymium-doped yttrium aluminum garnet laser-a promising modality for the management of verrucous epidermal nevi. *Lasers Med Sci*. 2018;33(3):597-601.
12. Scarcella G, Dethlefsen MW, Nielsen MCE. Treatment of solar lentigines using a combination of picosecond laser and biophotonic treatment. *Clin Case Rep*. 2018;6(9):1868-1870.
13. Negishi K, Akita H, Matsunaga Y. Prospective study of removing solar lentigines in Asians using a novel dual-wavelength and dual-pulse width picosecond laser. *Lasers Surg Med*. 2018;50(8):851-858.
14. Vachiramon V, Iamsumang W, Triyangkulsri K. Q-switched double frequency Nd:YAG 532-nm nanosecond laser vs. double frequency Nd:YAG 532-nm picosecond laser for the treatment of solar lentigines in Asians. *Lasers Med Sci*. 2018;33(9):1941-1947.
15. Koren A, Niv R, Cohen S, Artzi O. A 1064-nm neodymium-doped yttrium aluminum garnet picosecond laser for the treatment of hyperpigmented scars. *Dermatol Surg*. 2019;45(5):725-729.

16. Bach DQ, Garcia MS, Eisen DB. Hyperpigmented burn scar improved with a fractionated 1550 nm non-ablative laser. *Dermatol Online J*. 2012;18(7):12.
17. Chan NPY, Ho SGY, Shek SYN, Yeung CK, Chan HH. A case series of facial depigmentation associated with low fluence q-switched 1,064 nm Nd:YAG laser for skin rejuvenation and melasma. *Lasers Surg Med*. 2010;42(8):712-719.
18. Lee M-C, Lin Y-F, Hu S, et al. A split-face study: comparison of picosecond alexandrite laser and Q-switched Nd:YAG laser in the treatment of melasma in Asians. *Lasers Med Sci*. 2018;33(8):1733-1738.
19. Chalermchai T, Rummaneethorn P. Effects of a fractional picosecond 1,064 nm laser for the treatment of dermal and mixed type melasma. *J Cosmet Laser Ther*. 2018;20(3):134-139.
20. Choi YJ, Nam JH, Kim JY, et al. Efficacy and safety of a novel picosecond laser using combination of 1 064 and 595 nm on patients with melasma: A prospective, randomized, multicenter, split-face, 2% hydroquinone cream-controlled clinical trial. *Lasers Surg Med*. 2017;49(10):899-907.
21. Weiss RA, McDaniel DH, Weiss MA, Mahoney AM, Beasley KL, Halvorson CR. Safety and efficacy of a novel diffractive lens array using a picosecond 755 nm alexandrite laser for treatment of wrinkles. *Lasers Surg Med*. 2017;49(1):40-44.
22. Ansari F, Sadeghi-Ghyassi F, Yaaghoobian B. The clinical effectiveness and cost-effectiveness of fractional CO_2 laser in acne scars and skin rejuvenation: a meta-analysis and economic evaluation. *J Cosmet Laser Ther*. 2018;20(4):248-251.
23. Munavalli G. A Split-face assessment of the synergistic potential of sequential Q-switched Nd:YAG laser and 1565 nm fractional nonablative laser treatment for facial rejuvenation in Fitzpatrick skin type II-V patients. *J Drugs Dermatol*. 2016;15(11):1335-1342.
24. DiBernardo BE, Pozner JN. Intense pulsed light therapy for skin rejuvenation. *Clin Plast Surg*. 2016;43(3):535-540.
25. Westerhof W, Gamei M. Treatment of acquired junctional melanocytic naevi by Q-switched and normal mode ruby laser. *Br J Dermatol*. 2003;148(1):80-85.
26. Baba M, Bal N. Efficacy and safety of the short-pulse erbium:YAG laser in the treatment of acquired melanocytic nevi. *Dermatol Surg*. 2006;32(2):256-260.
27. Alshami MA. Long-pulsed 532-nm Nd:YAG laser treatment for small acquired melanocytic nevi in a single session: an 8-year study on 350 Yemeni patients. *J Cosmet Laser Ther*. 2014;16(1):14-20.
28. Lee SE, Choi JY, Hong KT, Lee KR. Treatment of acquired and small congenital melanocytic nevi with combined Er. *Dermatol Surg*. 2015;41(4):473-480.
29. Yu W, Zhu J, Yu W, Lyu D, Lin X, Zhang Z. A split-face, single-blinded, randomized controlled comparison of alexandrite 755-nm picosecond laser versus alexandrite 755-nm nanosecond laser in the treatment of acquired bilateral nevus of Ota-like macules. *J Am Acad Dermatol*. 2018;79(3):479-486.
30. Wong THS. Picosecond laser treatment for acquired bilateral nevus of Ota-like macules. *JAMA Dermatol*. 2018;154(10):1226-1228.
31. Peng L, Yang Y, Ge YP, Lin T. Picosecond alexandrite laser for Naevus of Ota treatment in Chinese. *J Eur Acad Dermatol Venereol*. 2018;32(7):e276-e277.
32. Zaleski-Larsen LA, Jones IT, Guiha I, Wu DC, Goldman MP. A Comparison study of the nonablative fractional 1565-nm Er: glass and the picosecond fractional 1064/532-nm Nd: YAG lasers in the treatment of striae alba: a split body double-blinded trial. *Dermatol Surg*. 2018;44(10):1311-1316.
33. Wu DC, Goldman MP. Successful treatment of chronic venous stasis hyperpigmentation of the lower limbs with the picosecond alexandrite laser. *Dermatol Surg*. 2018;44(6):881-883.
34. Lee YJ, Shin HJ, Noh TK, Choi KH, Chang SE. Treatment of melasma and post-inflammatory hyperpigmentation by a picosecond 755-nm alexandrite laser in Asian patients. *Ann Dermatol*. 2017;29(6):779-781.
35. Momosawa A, Kurita M, Ozaki M, et al. Combined therapy using Q-switched ruby laser and bleaching treatment with tretinoin and hydroquinone for periorbital skin hyperpigmentation in Asians. *Plast Reconstr Surg*. 2008;121(1):282-288.
36. Xu T-H, Yang Z-H, Li Y-H, et al. Treatment of infraorbital dark circles using a low-fluence Q-switched 1,064-nm laser. *Dermatol Surg*. 2011;37(6):797-803.
37. Ma G, Lin X-X, Hu X-J, Jin Y-B, Chen H. Treatment of venous infraorbital dark circles using a long-pulsed 1,064-nm neodymium-doped yttrium aluminum garnet laser. *Dermatol Surg*. 2012;38(8):1277-1282.
38. Katz TM, Goldberg LH, Firoz BF, Friedman PM. Fractional photothermolysis for the treatment of postinflammatory hyperpigmentation. *Dermatol Surg*. 2009;35(11):1844-1848.
39. Moody MN, Landau JM, Goldberg LH, Friedman PM. Fractionated 1550-nm erbium-doped fiber laser for the treatment of periorbital hyperpigmentation. *Dermatol Surg*. 2012;38(1):139-142.
40. Tanzi EL, Alster TS. Comparison of a 1450-nm diode laser and a 1320-nm Nd: YAG laser in the treatment of atrophic facial scars: a prospective clinical and histologic study. *Dermatol Surg*. 2004;30(2):152-157.
41. Huang CH, Chern E, Peng JH, Hsien-Li PP. Noninvasive atrophic acne scar treatment in asians with a 755-nm picosecond laser using a diffractive optic lens-a retrospective photographic review. *Dermatol Surg*. 2019;45(2):195-202.
42. Dierickx C. Using normal and high pulse coverage with picosecond laser treatment of wrinkles and acne scarring: long term clinical observations. *Lasers Surg Med*. 2018;50(1):51-55.
43. Wat H, Yee-Nam Shek S, Yeung CK, Chan HH. Efficacy and safety of picosecond 755-nm alexandrite laser with diffractive lens array for non-ablative rejuvenation in Chinese skin. *Lasers Surg Med*. 2019;51(1):8-13.

How to cite this article: Mehrabi JN, Friedman O, Al-Niaimi F, Artzi O. Retrospective photographic review of nontattoo indications treated by picosecond laser. *J Cosmet Dermatol*. 2020;19:612–621. https://doi.org/10.1111/jocd.13285