

## REVIEW ARTICLE

# Non-cosmetic dermatological uses of botulinum neurotoxin

E. Forbat,<sup>1</sup> F.R. Ali,<sup>2</sup> F. Al-Niimi<sup>2,\*</sup><sup>1</sup>King Edward VII Hospital, London, UK<sup>2</sup>Dermatological Surgery & Laser Unit, St John's Institute of Dermatology, St Thomas' Hospital, London, UK

\*Correspondence: F. Al-Niimi. E-mail: firas55@hotmail.com

## Abstract

Botulinum neurotoxin (BoNT) is renowned for its inhibitory effects on the neuromuscular junction. The evidence for its use in cosmetic dermatology and in non-dermatological indications is well established. We have systemically analysed the evidence for the non-cosmetic dermatological uses of BoNT. This review presents the many small studies showing promising results for the use of BoNT in a multitude of dermatological diseases, including (but not limited to) hyperhidrosis, Darier's disease, Hailey–Hailey disease, pompholyx and hidradenitis suppurativa. There is, however, the need for larger, double-blinded randomized control trials against established treatments to cement the evidence base underlying the use of BoNT in dermatology.

Received: 13 January 2016; Accepted: 19 April 2016

## Conflicts of interest

None.

## Funding sources

None.

## Introduction

Botulinum neurotoxin (BoNT), colloquially referred to as 'Botox', is widely regarded as synonymous with the world of cosmetic dermatology. Since identification of *Clostridium botulinum* and the deadly neurotoxin it produces,<sup>1</sup> the ability of BoNT to paralyse muscles has been exploited for a host of cosmetic and non-cosmetic indications (summarized in Table 1). In this article, we review the mechanism of action of BoNT and the evidence base underlying its use in dermatological practice.

## Mechanism of action

There are seven structurally distinct isoforms of BoNT (A–G).<sup>2,3</sup> BoNT-A (trade names: *Botox*, *Dysport*, *Xeomin*, *Prosigne*, *Blocs*, *Azzalure*, *Boccatore*) is most commonly used, followed by BoNT-B (trade names: *Myoblocs*, *Neuro Blocs*). BoNT-A and BoNT-B both consist of a protein comprising a heavy and light chain linked by a disulphide bond.<sup>4</sup> The heavy chain binds the neurotoxin to the cholinergic nerve terminal, while the light chain inhibits acetylcholine release.<sup>4,5</sup> BoNT-A and BoNT-B are pharmacologically distinguished by the type of protein the light chain cleaves, SNAP 25 in the case of BoNT-A and VAMP in the case of BoNT-B.<sup>6</sup>

BoNT's most recognized mechanism of action is to inhibit acetylcholine release at the presynaptic neuromuscular junction. As acetylcholine is also a neurotransmitter of the autonomic

nervous system, BoNT can block both sympathetic and parasympathetic nerve endings.<sup>7</sup> BoNT's ability to prevent acetylcholine binding to postsynaptic receptors within the eccrine sweat gland and inhibit sweat production has led to its extensive use in the management of hyperhidrosis.<sup>8</sup> Furthermore, it has been suggested that BoNT exerts anti-nociceptive action via blocking the action of substance P, hence it is, more recent, used in myofascial pain syndromes and headaches.<sup>9</sup>

## Side-effects and toxicity of BoNT

Side-effects include those expected with any minor procedure (infection, pain, localized bruising and failure of action) and those caused by unintentional migration of the neurotoxin to a non-target organ (e.g. blepharoptosis, when toxin diffuses from glabellar region to levator palpebrae muscle).<sup>5</sup> Contraindications to the use of BoNT include neuromuscular diseases, such as myasthenia gravis and Lambert–Eaton syndrome, in which the effect of the toxin may be potentiated,<sup>10</sup> as well as amyotrophic lateral sclerosis and motor neuropathies. BoNT is not recommended during pregnancy or in breast-feeding women.

It is believed that BoNT-B has more autonomic side-effects than BoNT-A. An open controlled study of 30 patients treated with BoNT suggested that autonomic side-effects occur more often with BoNT-B,<sup>11</sup> leading the authors to conclude that BoNT-B is relatively contraindicated in patients taking

**Table 1** Non-cosmetic indications of botulinum neurotoxin

Indication	Studies
<b>Hyperhidrosis</b>	
Axillary hyperhidrosis	22,25
Palmar hyperhidrosis	26,27
Chromhidrosis	20,29
Frey's syndrome	30
Stump hyperhidrosis	32,34–38
Eccrine naevus	39
<b>Pruritic dermatoses</b>	
Notalgia paraesthetica	40,41
Pompholyx	43,48
Idiopathic pruritus	44,47
Lichen simplex	49
Aquagenic keratoderma	50
Fox–Fordyce disease	51
<b>Acantholytic disorders</b>	
Hailey–Hailey disease	55–57
Darier's disease	58
<b>Inflammatory dermatoses</b>	
Hidradenitis suppurativa	59–61
Flexural psoriasis	62
Folliculitis decalvans	64
<b>Scarring</b>	
Reduction in graft contraction	69
Painful keloid scars	70
<b>Fissures and ulceration</b>	
Anal fissures	72,73,87
Raynaud's disease: ulcers	74,75
Exposure keratopathy	77,78
Oromandibular dystonia: ulceration	79
<b>Miscellaneous</b>	
Contractile urostomies and ileostomies	80
Vulvodynia	81–84
Cutaneous leiomyomas	85
Bromhidrosis	86

concomitant anti-cholinergic medication or those with autonomic dysfunction, however, may be beneficial to patients with sialorrhoea or hyperhidrosis.<sup>11,12</sup> Side-effects noted included dry mouth, reduced sweating, dysphagia, dyspepsia, constipation, micturition difficulties and thrush.<sup>11</sup> Of note, the duration of effect is shorter in BoNT-B, lasting 2 months less than BoNT-A in the treatment of dystonia.<sup>13</sup>

More recent studies are now investigating the possibility of patients producing neutralizing antibodies to BoNT after multiple treatments as evidenced by reduced efficacy in dystonia following repeated injections.<sup>14</sup> Antibody production is related to younger age of commencing BoNT and higher units of injection (per dose and cumulatively).<sup>15</sup> Rare side-effects of BoNT include dysphagia, diplopia and headaches<sup>16</sup> and weakness of the small muscles of the hand with palmar BoNT treatment.<sup>17</sup>

## Hyperhidrosis

Hyperhidrosis, in which eccrine glands produce excessive secretions, can have profound psychological impact upon quality of life. The excessive sweating is due to an abnormal physiological response to the hypothalamus, which can affect any eccrine sweat gland,<sup>18</sup> but most commonly involving the palms, soles and axillae.<sup>18</sup> The eccrine sweat glands in patients with hyperhidrosis are morphologically normal,<sup>19</sup> but are stimulated by excessive acetylcholine. BoNT is not only able to suppress eccrine secretion by blocking the cholinergic stimulation of apocrine glands,<sup>20</sup> but may also exert its effect through blocking substance P.<sup>21</sup>

A multi-centre, randomized placebo-controlled trial of BoNT-A treatment of bilateral primary axillary hyperhidrosis found that 94% of the treatment group ( $n = 242$ ) had greater than 50% reduction in sweating from baseline at weeks 1, 4 and 16 when treated with 50 U of BoNT-A (Botox, Allergan, Westport, Ireland) compared with only 36% of the placebo group ( $n = 78$ ).<sup>22</sup> A multi-centre, double-blind randomized controlled trial (RCT) evaluated the use of BoNT-A (vs. placebo) in the treatment of primary axillary hyperhidrosis over 52 weeks ( $n = 322$ ), but here a variation in units was used (75 or 50 U), finding a 75% significant reduction in sweating (in the group given either 75 or 50 U) vs. a 25% reduction in the placebo group. Interestingly, the duration of effect was found to be slightly longer in the 50 U group (205 days), lasting 8 days longer than the 75 U group (197 days).<sup>23</sup> Wollina *et al.* found that high dose of BoNT-A is able to prolong the anhidrotic effect of intradermal BoNT-A in the majority of patients.<sup>24</sup> A similar study focusing on palmar hyperhidrosis also corroborates that BoNT response is dose dependent, demonstrating that 200 U of BoNT-A (Botox, Allergan) per palm significantly prolongs the remission by at least 12 months in comparison to low-dose therapy (28–165 U).<sup>17</sup>

A more recent study of 24 patients comparing BoNT-A 50 U vs. BoNT-B 1500 U in the treatment of axillary hyperhidrosis over a 20-week period showed no difference in anhidrotic effect between the two variants of BoNT.<sup>25</sup>

A randomized double-blind study of 11 patients evaluated the benefit of BoNT-A (120 U) in palmar hyperhidrosis, demonstrating a 26%, 26% and 31% reduction in sweating at 4, 8 and 13 weeks, respectively (statistically significant), as measured by ninhydrin-stained sheet.<sup>26</sup> An intra-subject comparative study ( $n = 19$ ) evaluating the safety and efficacy of BoNT-A for palmar hyperhidrosis demonstrated statistically significant improvement with BoNT-A on one hand vs. normal saline on the other.<sup>27</sup> With respect to side-effects following BoNT injection for palmar hyperhidrosis, a study of 427 patients found that 275 (64%) patients reported local pain and 102 (24%) patients muscle weakness post BoNT-A injection (75–100 U; Botox, Allergan).<sup>28</sup>

Chromhidrosis is a rarer subset of hyperhidrosis, whereby coloured sweat is secreted from apocrine sweat glands.<sup>20</sup> A case report found a young woman with facial chromhidrosis, previously unsuccessfully treated with aluminium salts responded well to two applications of BoNT-A (20 U; Botox, Allergan), with the effect persisting at 19 weeks post-treatment.<sup>20</sup> Similar results were noted at 4 months in another case report of facial chromhidrosis treated with BoNT-A (30 U; Botox, Allergan).<sup>29</sup>

Frey's syndrome is a form of localized sweating of the parotid area associated with Erythema<sup>29</sup> during mastication, often attributed to trauma or surgery in that region.<sup>30</sup> The mechanism is thought to be secondary to the parasympathetic cholinergic nerve fibres aberrantly regenerating with sympathetic cholinergic receptors of the skin.<sup>30</sup> Treatment can be difficult, with options including atropine, anti-perspirants or preventative measures such as neurectomy.<sup>31</sup> One study included seven patients with Frey's syndrome (with at least 12 months of gustatory sweating) who were treated with 5–30 U BoNT-A (Botox, Allergan). Using a starch–iodine test to detect sweating, varying degrees of recurrence were noted. Some patients required no treatment at 12–24 months after a single dose of BoNT-A (12.5 U; Botox, Allergan), whereas others needed repeated treatments over this time period.<sup>30</sup>

Stump hyperhidrosis, a condition frequently noted in leg amputee patients, is often difficult to treat. Minimal results have been found with topical astringent agents and water iontophoresis.<sup>29</sup> To prevent stump hyperhidrosis in a 44-year-old amputee with diabetes, 100 U of BoNT-A (Botox, Allergan) injected into the stump was reported. Initially, there was relapse at 4 months attributed to sweat transposition from higher up the stump. BoNT-A subsequently injected higher up the thigh improved the duration of anhidrosis (a total of 200 U given to the anterior and posterior superior thigh), with no relapse observed at 7 months.<sup>32</sup>

A subsequent cohort of nine amputees reported a significant improvement in sweating at 4 weeks ( $P = 0.027$ ) and 3 months ( $P = 0.020$ ) following injection of BoNT-B 1750 U.<sup>33</sup> There have been many small studies showing similar outcomes,<sup>32,34–38</sup> however further studies with greater numbers of patients are needed to assess this more conclusively.

Eccrine naevus is a rare subset of hyperhidrosis associated with naevi.<sup>39</sup> One case report suggested a 50% reduction in sweating of an affected naevus following injection of 2 U BoNT-A (Botox, Allergan) with the effect lasting for 6 months.<sup>39</sup>

### Pruritic dermatoses

It has been shown that BoNT can ameliorate the symptom of pruritus, including in conditions such as notalgia Paraesthetica,<sup>40–42</sup> pompholyx<sup>43</sup> and idiopathic pruritus.<sup>44</sup> Animal models suggest BoNT-A inhibits mediators implicated in pruritus, such as substance P and glutamate.<sup>45</sup> Furthermore, Schemlitz *et al.*<sup>46</sup>

demonstrated that acetylcholine sensitive c-fibres are also associated with pruritus.

A small double-blind, placebo-controlled study of 14 patients with pruritus induced by histamine prick test showed that 5 U of BoNT-A (Botox, Allergan) significantly reduced pruritus intensity and area in comparison to normal saline injections. Laser Doppler imaging carried out as part of the study also revealed that BoNT reduced the vasomotor action in the treated area.<sup>47</sup>

An intra-individual study of 10 patients investigated the use of BoNT-A (mean dose 162 U; Botox, Allergan) for pompholyx, using the untreated side as control. It found that 70% of patients subjectively reported an improvement with a 39% decrease in pruritus reported in the treated side vs. a 52% increase in the untreated side. The authors hypothesized the increase in symptomatic pruritus could be due to compensatory hyperhidrosis.<sup>43</sup> A further study involving six patients corroborated these findings with 100 U of BoNT-A (Botox, Allergan), suggesting that anhidrosis induced by BoNT can improve symptoms of pompholyx and reduce the number of relapses.<sup>48</sup> While both studies were limited by the modest sample size and subjective assessment tool, BoNT may be of use in recalcitrant cases of pompholyx.<sup>43</sup>

An open pilot study of four patients investigating the effects of BoNT-A (20–80 U; Dysport, Ipsen Biopharmaceuticals Limited) on pruritus associated with lichen simplex found that pruritus not only subsided but also some of the clinical lesions fully resolved within 4 weeks.<sup>49</sup> Treatment of aquagenic keratoderma with BoNT-A was suggested to resolve symptoms of pruritus and pain triggered by immersion in water in a single case study.<sup>50</sup>

Fox–Fordyce disease is a rare pruritic disorder most evident on skin with a high density of apocrine glands. Symptomatic pruritic papules have been shown to be responsive to 100 U of BoNT-A (Botox, Allergan) when injected into axillae, with an associated reduction in papules.<sup>51</sup>

### Acantholytic disorders

Hailey–Hailey disease is an autosomal dominant acantholytic disorder with mutation of *ATP2C1* gene, clinically manifesting as macerated flexural erythema.<sup>52</sup> Heat and sweat aggravate the disease, resulting in worsening of discomfort and pruritus symptoms. BoNT could rationally ameliorate all the above via its inhibition of acetylcholine and substance P.<sup>53</sup> Several case reports have evidenced improvement of Hailey–Hailey with the use of BoNT-A (50–125 U; Botox, Allergan).<sup>54–57</sup> One case report compared BoNT-A with more conventional treatments of dermabrasion and Er:YAG laser therapy and found it to be equivalent, suggesting that BoNT may be a viable alternative to those not tolerating ablative treatments.<sup>56</sup>

Darier's disease is another autosomal dominant acantholytic disorder, with mutation of the *ATP2A2* gene. Manifestations

include greasy warty papules in the flexures and heavily eccrine populated areas, which contribute to malodour.<sup>58</sup> Evidence for BoNT use in Darier's disease is limited with only a letter examining a case of improvement in one patient who received an injection of 100 U BoNT-A (Botox, Allergan).<sup>58</sup>

### Inflammatory dermatoses

Hidradenitis suppurativa (HS) is a chronic inflammatory dermatosis of the apocrine glands which typically affects the axillae and groin<sup>59</sup> and treatment is often challenging. There are several case reports showing improvement of symptoms with BoNT-A,<sup>59–61</sup> attributed to the inhibition of sweating. A 46-year-old lady with chronic severe HS (Hurley stage 2) was reported to respond very well to axillary BoNT-A treatment (50 U) with a remission period of at least 12 months. This patient had previously been managed with antibiotics, the oral contraceptive pill and surgical drainage of secondary abscesses. The authors hypothesized that BoNT-A inhibits apocrine secretions thereby preventing the inflammatory response evoked by follicular material from the pilosebaceous unit.<sup>60</sup>

BoNT has been trialled in other inflammatory dermatoses that are thought to be exacerbated by excessive sweating. A pilot study of 15 patients with flexural psoriasis showed that 50–100 U of BoNT-A (Botox, Allergan) improved subjective symptoms and objective photographic evidence of disease in 87% of patients at 2, 4 and 12 weeks.<sup>62</sup> Furthermore, patients with psoriasis are known to have a higher concentration of substance P receptors in their skin,<sup>63</sup> meaning BoNT should theoretically reduce pruritus by inhibiting substance P and hence prevent binding to the multiple receptors.

Folliculitis decalvans is a primary neutrophilic cicatricial alopecia.<sup>64</sup> One case study found favourable effects on hair regrowth post-injection of 60–150 U of BoNT-A (Botox, Allergan). They hypothesized that BoNT-A inhibition of immune factors and cytokines reduced follicular inflammation.<sup>65</sup>

### Scarring

BoNT can be used to reduce or soften troublesome scars, particularly those in areas with extensive muscular activity, such as the upper forehead. If a scar does not naturally conform, then BoNT has been used to settle tension created by the muscular activity beneath the scar, with injection of 17.5–40 U of BoNT-A previously trialled (Botox, Allergan).<sup>66</sup> BoNT can be injected either at the time of scar formation (if anticipated) or at suture removal. Apart from muscular inhibition, BoNT is thought to inhibit the action of fibroblasts and hence reduce scar hypertrophy.<sup>67</sup> A randomized, double-blind, placebo-controlled study of primates found a significant improvement in scars injected with BoNT (when analysed by plastic surgeons) in comparison to those that were not ( $P < 0.01$ ).<sup>68</sup>

Plastic surgeons have reviewed the role of BoNT in full thickness wounds, primarily because the cosmetic outcome with

grafts can be poor secondary to graft contraction. One study using a rodent population, found a significant reduction in graft contraction 1 month post BoNT injection ( $P < 0.05$ ) with an associated reduction in fibroblasts ( $P < 0.05$ ) and inflammation.<sup>69</sup>

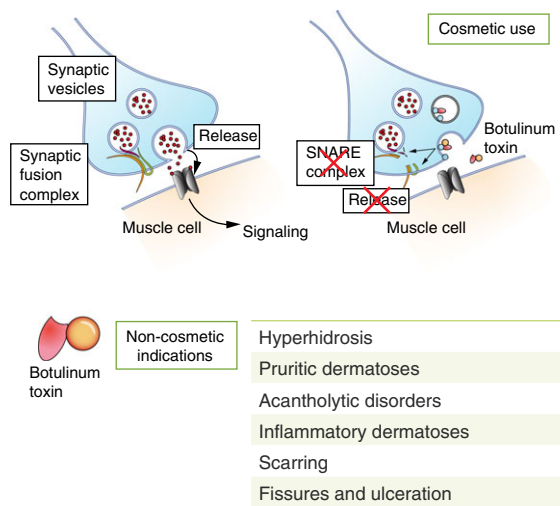
Keloid scars are a common complication of skin incisions, the incidence varying between races and also location of the incision. BoNT is often quoted as an emerging treatment of keloid scars, however, there are few studies to evidence this.<sup>70</sup> An 80-year-old female with a painful keloid scar on the chest wall, previously unsuccessfully treated with triamcinolone, bupivacaine injections, lidocaine patches, gabapentin and opioids, reported a significant improvement following injection of 100 U of BoNT-A (Botox, Allergan) into the scar.<sup>71</sup> The underlying mechanism of action remains largely unknown, with one study identifying no effect of BoNT upon cytokine and growth factor production of keloid tissue in cell culture.<sup>72</sup>

### Fissures and ulceration

The efficacy of BoNT-A is well established in the treatment of anal fissures. Chronic anal fissures arise due to hypertonia of the anal sphincters (particularly the internal anal sphincter), which subsequently cause ischaemia of the arterial circulation and therefore pain.<sup>73</sup> A review of treatments of anal fissures demonstrated a 53–88% healing rate following BoNT treatment (15–200 U) into the internal anal sphincter.<sup>74</sup> The studies reviewed had a variable sample size (ranging from 10 to 100), varying site of injection and varying doses injected. All studies however demonstrated healing or improvement with either no side-effect or transient incontinence, haematoma or burning sensation post-injection.<sup>74</sup>

A 2009 retrospective study has found that 84% of patients with Raynaud's disease and associated chronic ischaemic hand pain ( $n = 19$ ) reported reduced pain post BoNT-A injection (50–100 U), as well as increased blood flow.<sup>75</sup> One review evaluated the use of BoNT in Raynaud's ulcers in four studies since 2004. Ulcers appeared to heal more rapidly following BoNT-A injection (10–100 U), however there were multiple limitations of the small studies included, highlighting the need for larger studies,<sup>76</sup> with the exact mechanism of BoNT in Raynaud's ulcers remaining unknown. BoNT has also been shown to be an alternative to surgical tarsorrhaphy (indicated, e.g., in exposure keratopathy, dry eye syndrome or persistent epithelial defects<sup>77</sup>) by inducing a protective ptosis through injection of BoNT-A (2.5–5 U) into the levator palpebrae superioris muscle, and thus preventing or resolving corneal ulceration.<sup>78</sup> BoNT-A can also be used to prevent wound complications post-ophthalmic procedures, with prevention of wound dehiscence when used post-eyelid reconstruction.<sup>79</sup>

Neurodegenerative disorders can often result in chronic lip biting or oromandibular dystonia, leading to ulceration, megalencephalic leukoencephalopathy being one such example. A case study on a 10-year-old boy treated with 20 U of BoNT-A



**Figure 1** Botulinum toxin: mechanism of action and non-cosmetic dermatological indications.

(Botox, Allergan) resulted in reduced dystonia and subsequent healing of the ulcer.<sup>80</sup>

### Miscellaneous indications

A prospective case series of 10 patients with contractile stomas (including urostomies and ileostomies) and associated leaks (with consequent peri-stomal irritant dermatitis) found that seven patients had a reduction in leakage following BoNT injection (50–100 U) into the muscularis layer of the rectus sheath. Less frequent pouch changes were subsequently required and quality of life markedly improved.<sup>81</sup>

Several case studies have evaluated the role of BoNT injections in refractory cases of vulvodynia<sup>82,83</sup> and found that BoNT-A is effective in blocking nociception associated with the vestibule. One case study was unable to assess the long-term effectiveness of BoNT as the patient opted for a vestibulectomy.<sup>82</sup> A separate study found that all subjects included ( $n = 7$ ) had a reduction in pain following injection of 20–40 U BoNT (Botox, Allergan), but there was variation in the number of injections required.<sup>83</sup> BoNT injection with progressive dilatation has been shown to be safe and effective in women suffering from vaginismus (10–150 U).<sup>83–85</sup>

Haley *et al.* recently published a randomized, double-blind, placebo-controlled pilot over 5 years on the use of BoNT in painful cutaneous leiomyomas. Cutaneous leiomyomas are extremely painful, resistant to current treatment options and well renowned for their impact on patient quality of life (QoL). This study found reduced pain severity post BoNT injection (5 U per cm<sup>2</sup>) and improved QoL, albeit not statistically significant. This may be attributed to the small sample size ( $n = 18$ ). This was a single centre study, limited by subjective measure of pain, variation in gender between study

arms and a varied distribution and location of leiomyomas. However, it does highlight that further research is required for the use of BoNT in cutaneous pain disorders. The authors also hypothesized that pain is reduced via BoNT exerting cholinergic blockage.<sup>86</sup> Finally, body malodour (bromhidrosis) is also reported to respond to BoNT, whether associated with hyperhidrosis.<sup>87</sup>

### Discussion

BoNT has a multitude of non-cosmetic, dermatological indications for which it is able to either improve disease symptoms or treat the disease entirely. The use of BoNT in dermatological practice may be of particular value in cases of diseases refractory to other treatments (Fig. 1).

While there are many case examples within each disease category we have highlighted, there are few double-blinded randomized controlled trials, which are needed in order to compare BoNT to more commonly used, established treatments. Trials involving larger numbers of patients that include comparisons of dosage of therapy and subtypes of BoNT are lacking. Furthermore, the effect of the experience and training of the clinician administering BoNT on disease and symptom outcomes is yet to be explored.

The best evidence to date belies the use of BoNT in hyperhidrosis. Interestingly, some of the dermatological conditions we have discussed appear to respond to inhibition of sweating such as Hailey–Hailey disease and stump hyperhidrosis in amputees, lending support to BoNT can be used as an adjunct in recalcitrant disease. Other uses of BoNT may be seen in multi-disciplinary clinics, such as the use of BoNT for the treatment of anal fissures and retracted stomas that were causing peristomal dermatitis. Pruritus can be a result or an instigator of dermatological conditions. Evidence to date suggests BoNT can relieve pruritus, perhaps via its anhidrotic effects, therefore potentially easing the symptoms of many dermatological diseases. The cost of BoNT, transient nature of response and difficulty procuring funding from local commissioning groups will undoubtedly discourage its use by some dermatologists.

BoNT is a well-tested, relatively safe treatment and should be considered by dermatologists as a therapeutic possibility, particularly in recalcitrant cases of skin diseases.

### References

- Boldt GE, Kennedy JP, Hixon MS *et al.* Synthesis, characterization and development of a high-throughput methodology for the discovery of botulinum neurotoxin A inhibitors. *J Comb Chem* 2006; **8**: 513–521.
- Dover N, Barash JR, Hill KK, Xie G, Arnon SS. Molecular characterization of a novel botulinum neurotoxin type H gene. *J Infect Dis* 2014; **209**: 192–202.
- Montecucco C, Rasotto MB. On Botulinum Neurotoxin Variability. *MBio* 2015; **6**: e02131–14.
- Schmid MF, Robinson JP, DasGupta B. Direct visualization of botulinum neurotoxin-induced channels in phospholipid vesicles. *Nature* 1993; **364**: 827–830.



- 5 Carruthers A. Botulinum toxin type A: history and current cosmetic use in the upper face. *Dis Mon* 2002; **48**: 299–322.
- 6 Aoki KR, Guyer B. Botulinum toxin type A and other botulinum toxin serotypes: a comparative review of biochemical and pharmacological actions. *Eur J Neurol* 2001; **8**: 21–29.
- 7 Giralda P, Vita G, Nicolosi C, Milone S, Messina C. Botulinum toxin therapy: distant effects on neuromuscular transmission and autonomic nervous system. *J Neurol Neurosurg Psychiatry* 1992; **55**: 844–845.
- 8 Kreyden OP, Scheidegger EP. Anatomy of the sweat glands, pharmacology of botulinum toxin, and distinctive syndromes associated with hyperhidrosis. *Clin Dermatol* 2004; **22**: 40–44.
- 9 Aoki KR. Evidence for antinociceptive activity of botulinum toxin type A in pain management. *Headache* 2003; **43**: 9–15.
- 10 Dressler D. Subclinical myasthenia gravis causing increased sensitivity to botulinum toxin therapy. *J Neural Transm* 1996; **2010**: 1293–1294.
- 11 Dressler D, Benecke R. Autonomic side effects of botulinum toxin type B treatment of cervical dystonia and hyperhidrosis. *Eur Neurol* 2003; **49**: 34–38.
- 12 Bentivoglio AR, Del Grande A, Petracca M, Ialongo T, Ricciardi L. Clinical differences between botulinum neurotoxin type A and B. *Toxicol* 2015; **107**(pt A): 77–84.
- 13 Foran PG, Mohammed N, Lisk GO et al. Evaluation of the therapeutic usefulness of botulinum neurotoxin B, C1, E, and F compared with the long lasting type A basis for distinct durations of inhibition of exocytosis in central neurons. *J Biol Chem* 2003; **278**: 1363–1371.
- 14 Chang MA. Possible adverse effects of repeated botulinum toxin A injections to decrease post-stroke spasticity in adults undergoing rehabilitation: a review of the literature. *J Allied Health* 2015; **44**: 140–144.
- 15 Jankovic J, Schwartz K. Response and immunoresistance to botulinum toxin injections. *Neurology* 1995; **45**: 1743–1746.
- 16 Wollina DU, Konrad H. Managing adverse events associated with botulinum toxin type A. *Am J Clin Dermatol* 2012; **6**: 141–150.
- 17 Wollina U, Karamfilov T. Botulinum toxin A for palmar hyperhidrosis. *J Eur Acad Dermatol Venereol* 2001; **15**: 555–558.
- 18 Glogau RG. Botulinum A neurotoxin for axillary hyperhidrosis. No sweat Botox. *Dermatol Surg* 1998; **24**: 817–819.
- 19 Haider A, Solish N. Focal hyperhidrosis: diagnosis and management. *Can Med Assoc J* 2005; **172**: 69–75.
- 20 Wu JM, Mamelak AJ, Nussbaum R, McElgunn PSJ. Botulinum toxin A in the treatment of chromhidrosis. *Dermatol Surg* 2005; **31**: 963–965.
- 21 Karsenty G, Denys P, Amarenco G et al. Botulinum toxin A (Botox®) intradetrusor injections in adults with neurogenic detrusor overactivity/neurogenic overactive bladder: a systematic literature review. *Eur Urol* 2008; **53**: 275–287.
- 22 Naumann M, Lowe NJ. Botulinum toxin type A in treatment of bilateral primary axillary hyperhidrosis: randomised, parallel group, double blind, placebo controlled trial. *BMJ* 2001; **323**: 596.
- 23 Lowe NJ, Glaser DA, Eadie N, Daggett S, Kowalski JW, Lai P-Y. Botulinum toxin type A in the treatment of primary axillary hyperhidrosis: a 52-week multicenter double-blind, randomized, placebo-controlled study of efficacy and safety. *J Am Acad Dermatol* 2007; **56**: 604–611.
- 24 Wollina U, Karamfilov T, Konrad H. High-dose botulinum toxin type A therapy for axillary hyperhidrosis markedly prolongs the relapse-free interval. *J Am Acad Dermatol* 2002; **46**: 536–540.
- 25 An JS, Hyun Won C, Si Han J, Park HS, Seo KK. Comparison of onabotulinumtoxinA and rimabotulinumtoxinB for the treatment of axillary hyperhidrosis. *Dermatol Surg* 2015; **41**: 960–967.
- 26 Schnider P, Binder M, Auff E, Kittler H, Berger T, Wolff K. Double-blind trial of botulinum A toxin for the treatment of focal hyperhidrosis of the palms. *Br J Dermatol* 1997; **136**: 548–552.
- 27 Lowe NJ, Yamauchi PS, Lask GP, Patnaik R, Iyer S. Efficacy and safety of botulinum toxin type A in the treatment of palmar hyperhidrosis: a double-blind, randomized, Placebo-Controlled Study. *Dermatol Surg* 2002; **28**: 822–827.
- 28 Kouris A, Vavouli C, Markantoni V, Kontochristopoulos G. Muscle weakness in treatment of palmar hyperhidrosis with botulinum toxin type A: can it be prevented? *J Drugs Dermatol* 2014; **13**: 1315–1316.
- 29 Matarasso SL. Treatment of facial chromhidrosis with botulinum toxin type A. *J Am Acad Dermatol* 2005; **52**: 89–91.
- 30 Arad-Cohen A, Blitzer A. Botulinum toxin treatment for symptomatic Frey's syndrome. *Otolaryngol Head Neck Surg* 2000; **122**: 237–240.
- 31 Xiao M, Shi L, Liu Y. Effectiveness of acellular dermal matrix and parotid fascia in preventing Frey's syndrome: meta analysis. *Shanghai Kou Qiang Yi Xue* 2014; **23**: 628–633.
- 32 García-Morales I, Pérez-Bernal A, Camacho F. Letter: stump hyperhidrosis in a leg amputee: treatment with botulinum toxin A. *Dermatol Surg* 2007; **33**: 1401–1402.
- 33 Kern K-U, Kohl M, Seifert U, Schlereth T. Wirkung von Botulinumtoxin Typ B auf Stumpfschweitzen und Stumpfschmerzen: Besteht die Chance der indirekten Phantomschmerzreduktion durch bessere Prothesen-nutzung? *Schmerz* 2012; **26**: 176–184.
- 34 Wollina U, Konrad H, Graefe T, Thiele J. Botulinum toxin A for focal hyperhidrosis in leg amputees: a case report. *Acta Derm Venereol* 2000; **80**: 226–227.
- 35 Gratrix M, Hivnor C. Botulinum toxin A treatment for hyperhidrosis in patients with prosthetic limbs. *Arch Dermatol* 2010; **146**: 1314–1315.
- 36 Kern U, Kohl M, Seifert U, Schlereth T. Botulinum toxin type B in the treatment of residual limb hyperhidrosis for lower limb amputees: a pilot study. *Am J Phys Med Rehabil* 2011; **90**: 321–329.
- 37 Kern U, Martin C, Scheicher S, Müller H. Does botulinum toxin A make prosthesis use easier for amputees? *J Rehabil Med* 2004; **36**: 238–239.
- 38 Charrow A, DiFazio M, Foster L, Pasquina PF, Tsao JW. Intra-dermal botulinum toxin type A injection effectively reduces residual limb hyperhidrosis in amputees: a case series. *Arch Phys Med Rehabil* 2008; **89**: 1407–1409.
- 39 Vázquez MR and Gómez de la Fuente E. Eccrine naevus: case report and literature review [12]. *Acta Derm Venereol* 2002; **82**: 154–156.
- 40 Pérez-Pérez L, García-Gavín J, Allegue F, Caeiro JL, Fabeiro JM, Zulaica A. Notalgia paresthetica: treatment using intra-dermal botulinum toxin A. *Actas Dermosifiliogr* 2014; **105**: 74–77.
- 41 Yosipovitch G, Samuel LS. Neuropathic and psychogenic itch. *Dermatol Ther* 2008; **21**: 32–41.
- 42 Smith KC. Botulinum toxin type A: new information about an old medicine. *Skin Therapy Lett* 2011; **16**: 3–6.
- 43 Swartling C, Naver H, Lindberg M, Anveden I. Treatment of dyshidrotic hand dermatitis with intra-dermal botulinum toxin. *J Am Acad Dermatol* 2002; **47**: 667–671.
- 44 Salarini A, Richardson D, Jabbari B. Relief of intractable pruritus after administration of botulinum toxin A (botox): a case report. *Clin Neuropharmacol* 2008; **31**: 303–306.
- 45 Ishikawa H, Mitsui Y, Yoshitomi T et al. Presynaptic effects of botulinum toxin type A on the neuronally evoked response of albino and pigmented rabbit iris sphincter and dilator muscles. *Nippon Ganka Gakkai Zasshi* 2001; **105**: 218–222.
- 46 Schmelz M, Schmidt R, Bickel A, Handwerker HO, Torebjörk HE. Specific C-receptors for itch in human skin. *J Neurosci* 1997; **17**: 8003–8008.
- 47 Gazerani P, Pedersen NS, Drewes AM, Arendt-Nielsen L. Botulinum toxin type A reduces histamine-induced itch and vasomotor responses in human skin. *Br J Dermatol* 2009; **161**: 737–745.
- 48 Wollina U, Karamfilov T. Adjuvant botulinum toxin A in dyshidrotic hand eczema: a controlled prospective pilot study with left-right comparison. *J Eur Acad Dermatol Venereol* 2002; **16**: 40–42.
- 49 Heckmann M, Heyer G, Brunner B, Plewig G. Botulinum toxin type A injection in the treatment of lichen simplex: an open pilot study. *J Am Acad Dermatol* 2002; **46**: 617–619.
- 50 Bagazgoitia L, Pérez-Carmona L, Salgüero I, Harto A, Jaén P. Letter: aquagenic keratoderma: successful treatment with botulinum toxin. *Dermatol Surg* 2010; **36**: 434–436.

- 51 González-Ramos J, Alonso-Pacheco ML, Goiburú-Chenú B, Mayor-Ibarra A, Herranz-Pinto P. Successful treatment of refractory pruritic Fox-Fordyce disease with botulinum toxin type A. *Br J Dermatol* 2016; **174**: 458–459.
- 52 Engin B, Kutlubay Z, Çelik U, Serdaroglu S, Tüzün Y. Hailey-Hailey disease: a fold (intertriginous) dermatosis. *Clin Dermatol* 2015; **33**: 452–455.
- 53 Oliver M, MacDonald J, Rajwani M. The use of botulinum neurotoxin type A (Botox) for headaches: a case review. *J Can Chiropr Assoc* 2006; **50**: 263–270.
- 54 López-Ferrer A and Alomar A. Botulinum toxin A for the treatment of familial benign pemphigus. *Actas Dermo-Sifiliográficas* 2012; **103**: 532–535.
- 55 Bessa GR, Grazziotin TC, Manzoni AP, Weber MB, Bonamigo RR. Hailey-Hailey disease treatment with botulinum toxin type A. *An Bras Dermatol* 2010; **85**: 717–722.
- 56 Konrad H, Karamfilov T, Wollina U. Intracutaneous botulinum toxin A versus ablative therapy of Hailey-Hailey disease—a case report. *J Cosmet Laser Ther* 2001; **3**: 181–184.
- 57 Lapiere J-C, Hirsh A, Gordon KB, Cook B, Montalvo A. Botulinum toxin type A for the treatment of axillary Hailey-Hailey disease. *Dermatol Surg* 2000; **26**: 371–374.
- 58 Kontochristopoulos G, Katsavou AN, Kalogirou O, Agelidis S, Zakopoulou N. Letter: botulinum toxin type A: an alternative symptomatic management of Darier's disease. *Dermatol Surg* 2007; **33**: 882–883.
- 59 Feito-Rodríguez M, Sendagorta-Cudós E, Herranz-Pinto P, de Lucas-Laguna R. Prepubertal hidradenitis suppurativa successfully treated with botulinum toxin A. *Dermatol Surg* 2009; **35**: 1300–1302.
- 60 Khoo ABS, Burova EP. Hidradenitis suppurativa treated with Clostridium botulinum toxin A. *Clin Exp Dermatol* 2014; **39**: 749–750.
- 61 O'Reilly DJ, Pleat JM, Richards AM. Treatment of hidradenitis suppurativa with botulinum toxin A. *Plast Reconstr Surg* 2005; **116**: 1575–1576.
- 62 Zanchi M, Favot F, Bizzarini M, Piai M, Donini M, Sedona P. Botulinum toxin type-A for the treatment of inverse psoriasis. *J Eur Acad Dermatol Venereol* 2008; **22**: 431–436.
- 63 Staniek V, Doutremepuich J, Schmitt D, Claudy A, Misery L. Expression of substance P receptors in normal and psoriatic skin. *Pathobiology* 1999; **67**: 51–54.
- 64 Otberg N, Kang H, Alzolibani AA, Shapiro J. Folliculitis decalvans. *Dermatol Ther* 2008; **21**: 238–244.
- 65 Tamura BM, Sortino-Rachou AM, Cucé LC. Letter: folliculitis responds to botulinum toxin: is it possible? *Dermatol Surg* 2007; **33**: 1398–1400.
- 66 Gassner HG, Sherris DA. Chemoimmobilization: improving predictability in the treatment of facial scars. *Plast Reconstr Surg* 2003; **112**: 1464–1466.
- 67 Zhibo X, Miaobo Z. Botulinum toxin type A affects cell cycle distribution of fibroblasts derived from hypertrophic scar. *J Plast Reconstr Aesthetic Surg* 2008; **61**: 1128–1129.
- 68 Gassner HG, Sherris DA, Otley CC. Treatment of facial wounds with botulinum toxin A improves cosmetic outcome in primates. *Plast Reconstr Surg* 2000; **105**: 1948–1953; discussion 1954–5.
- 69 Gauglitz GG. Management of keloids and hypertrophic scars: current and emerging options. *Clin Cosmet Investig Dermatol* 2013; **6**: 103–114.
- 70 Uyesugi B, Lippincott B, Dave S. Treatment of a painful keloid with botulinum toxin type A. *Am J Phys Med Rehabil* 2010; **89**: 153–155.
- 71 Haubner F, Leyh M, Ohmann E, Sadick H, Gassner HG. Effects of botulinum toxin A on patient-specific keloid fibroblasts in vitro. *Laryngoscope* 2014; **124**: 1344–1351.
- 72 Simms HN, McCallion K, Wallace W, Campbell WJ, Calvert H, Moorehead RJ. Efficacy of botulinum toxin in chronic anal fissure. *Ir J Med Sci* 2004; **173**: 188–190.
- 73 Jost WH. Ten years' experience with botulin toxin in anal fissure. *Int J Colorectal Dis* 2002; **17**: 298–302.
- 74 Neumeister MW, Chambers CB, Herron MS *et al*. Botox therapy for ischemic digits. *Plast Reconstr Surg* 2009; **124**: 191–201.
- 75 Iorio ML, Masden DL, Higgins JP. Botulinum toxin A treatment of Raynaud's phenomenon: a review. *Semin Arthritis Rheum* 2012; **41**: 599–603.
- 76 Cosar CB, Cohen EJ, Rapuano CJ *et al*. Tarsorrhaphy: clinical experience from a cornea practice. *Cornea* 2001; **20**: 787–791.
- 77 Ellis MF, Daniell M. An evaluation of the safety and efficacy of botulinum toxin type A (BOTOX) when used to produce a protective ptosis. *Clin Experiment Ophthalmol* 2001; **29**: 394–399.
- 78 Choi JC, Lucarelli MJ, Shore JW. Use of botulinum A toxin in patients at risk of wound complications following eyelid reconstruction. *Ophthalmol Plast Reconstr Surg* 1997; **13**: 259–264.
- 79 Fantuzzo JJ, Rogér JM, Barroner MD, Karp JM. Self-mutilation of the lower lip in a child with dystonia secondary to megalencephalic leukoencephalopathy treated with botox injections: a case report. *J Oral Maxillofac Surg* 2014; **72**: 1327.e1–1327.e4.
- 80 Smith VM, Lyon CC. A Novel use for botulinum toxin A in the management of ileostomy and urostomy leaks. *J Wound Ostomy Continence Nurs* 2015; **42**: 83–88.
- 81 Gunter J, Brewer A, Tawfik O. Botulinum toxin A for vulvodynia: a case report. *J Pain* 2004; **5**: 238–240.
- 82 Yoon H, Chung WS, Shim BS. Botulinum toxin A for the management of vulvodynia. *Int J Impot Res* 2006; **19**: 84–87.
- 83 Pacik PT. Botox treatment for vaginismus. *Plast Reconstr Surg* 2009; **124**: 455e–456e.
- 84 Pacik PT. Vaginismus: review of current concepts and treatment using botox injections, bupivacaine injections, and progressive dilation with the patient under anesthesia. *Aesthetic Plast Surg* 2011; **35**: 1160–1164.
- 85 Naik HB, Steinberg SM, Middleton LA *et al*. Efficacy of intralesional botulinum toxin A for Treatment of painful cutaneous leiomyomas: a randomized clinical trial. *JAMA Dermatol* 2015; **151**: 1096–1102.
- 86 Heckmann M, Teichmann B, Pause BM, Plewig G. Amelioration of body odor after intracutaneous axillary injection of botulinum toxin A. *Arch Dermatol* 2003; **139**: 57–59.
- 87 Brisinda G, Albanese A, Cadeddu F *et al*. Botulinum neurotoxin to treat chronic anal fissure: results of a randomized 'Botox vs. Dysport' controlled trial. *Aliment Pharmacol Ther* 2004; **19**: 695–701.