BJD
British Journal of Dermatology

Peristomal lichen sclerosus: the role of occlusion and urine exposure?

F. Al-Niaimi[1] and C. Lyon[2]

[1]Guy's and St Thomas' Hospital, St John's Institute of Dermatology, London, U.K.
[2]Department of Dermatology, York Hospital, York, U.K.

Correspondence
Firas Al-Niaimi.
E-mail: firas55@hotmail.com

Accepted for publication
14 August 2012

Funding sources
None.

Conflicts of interest
None declared.

DOI 10.1111/bjd.12014

Summary

Background Lichen sclerosus (LS) is a chronic inflammatory skin disorder that typically affects the anogenital area. It presents with ivory-white atrophic patches or plaques with associated telangiectasia and occasional purpura. It has rarely been described as affecting abdominal stomas.
Objectives To investigate possible aetiological factors responsible for the development of this condition.
Methods All patients with peristomal LS were identified at a specialist stoma dermatology clinic and studied using a standardized pro forma.
Results We identified 12 patients with peristomal LS. The mean age was 72·3 years (range 47–85 years). With the exception of one patient, all our other patients had urostomies. Treatment was effective in the majority of cases.
Conclusions Peristomal LS, in our experience, is most commonly found around urostomies, and we speculate that in addition to the possible role of local trauma and occlusion, certain – as yet unidentified – constituents in the urine possibly play a role in its aetiology. It tends to respond well to corticosteroids and has not been associated with malignant transformation.

Lichen sclerosus (LS) is a chronic inflammatory skin disorder first described in 1887 by Hallopeau.[1] It typically affects the anogenital area and presents clinically with ivory-white atrophic patches or plaques with associated telangiectasia and purpura.[2]

Only four cases of peristomal LS have been reported in the literature, and it has been considered to be a variant of extragenital LS.[3–5] We present the clinical features of peristomal LS in a series of 12 patients, and discuss possible aetiological factors responsible for the development of this condition.

Patients and methods

We have run monthly stoma care and dermatology clinics for more than 10 years, during which time we have attended 845 new patients. The service receives referrals from clinicians nationally as well as locally. Where LS was suspected clinically, a skin biopsy was recommended. All patients presenting with a diagnosis of LS were identified. The data were analysed using a specifically designed pro forma. Data collected included age, sex, type of stoma, duration of stoma prior to the occurrence of LS, presence of leakage onto the skin, other skin problems, histology and management.

Results

In total we have identified 12 patients with peristomal LS (Fig. 1). The mean age of the 12 patients with confirmed LS was 72·3 years (range 47–85 years). There were seven women and five men. All but one of our patients with peristomal LS had a urostomy, the other had an ileostomy (Table 1). This woman suffered from ulcerative colitis and vulval LS and was considered to have an abdominal plaque of extragenital LS (Fig. 2).

The indications for the urostomies included bladder carcinoma, underlying neurological disorders and iatrogenic damage to the urogenital tract (one case). The onset of peristomal LS ranged from 2 to 15 years following surgery. Genital LS was definitely present in only three patients with a urostomy, all women, and this preceded the occurrence of the peristomal LS in all three cases. There was no evidence of genital LS in any of the men, although one patient had been circumcised many years earlier (case 6) for a tight foreskin, from which no histology was recorded. All the other men were uncircumcised. Leakage of urine onto the skin was noted by all patients to occur at least occasionally and was frequent in four cases (3, 5, 9 and 12).

All patients, with the exception of case 10, (Fig. 2) reported symptoms ranging from burning discomfort to

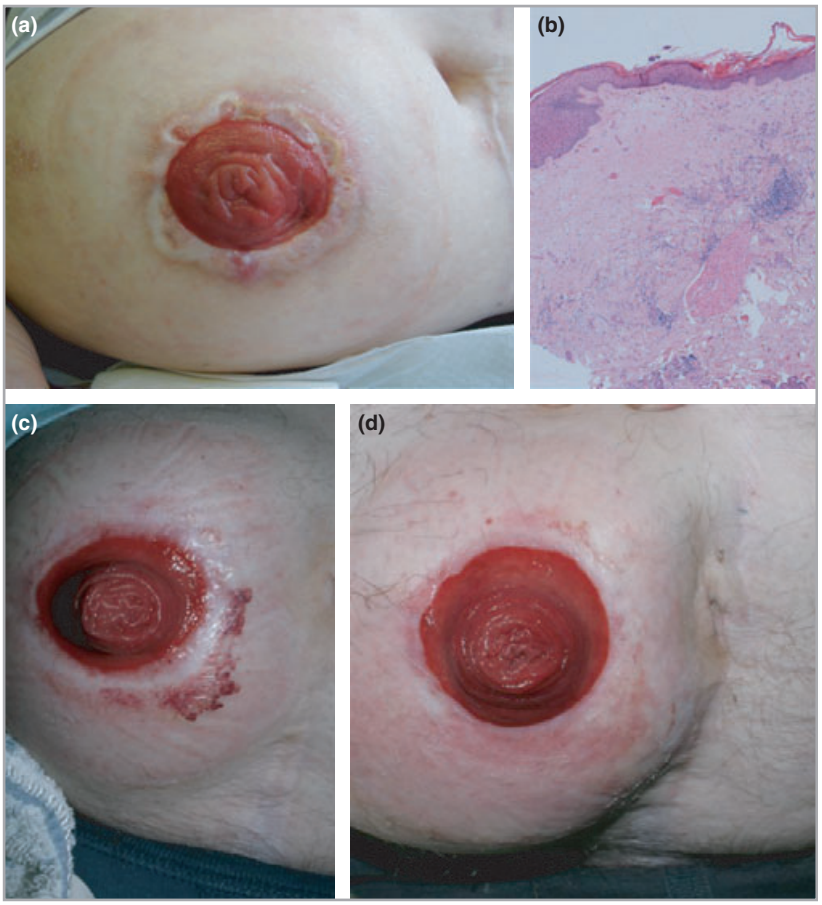

Fig 1. Lichen sclerosus. (a) Case 8 showing painfully ulcerated sclerotic plaques circumferentially around a urostomy. (b) Histology of a biopsy from the edge (×40) demonstrates hyperkeratosis, a subepidermal zone of hyalinization overlying a patchy inflammatory infiltrate. (c) Case 7 presented with more purpura and less ulceration, which was controlled with 4 weeks of daily applications with clobetasol propionate scalp lotion (d).

severe pain, particularly in the presence of ulceration or erosion (seven patients). Skin biopsies were obtained from nine cases and features were consistent with LS in all cases.

All of our patients with a urostomy responded well to daily treatment with potent corticosteroids either topically as a scalp solution (betamethasone valerate or clobetasol dipropionate) or intralesionally (triamcinolone acetonide, 20 mg). The latter proved more efficacious and is our standard second-line treatment if the topical application of potent corticosteroids proves ineffective. None of our patients developed dysplastic or malignant lesions on the peristomal LS area, with an average follow-up of 7 years to date.

Discussion

The aetiology of LS remains unexplained. Several mechanisms have been proposed, including autoimmunity, infections, genetics and Koebner's phenomenon due to local trauma.[6] However, it is possible that more than one of these mechanisms plays a role in the disease pathogenesis.[6,7]

Two of the four previously published reports of peristomal LS were women with colostomies[4] for bowel carcinoma. These were considered to be a form of extragenital LS because both cases had a long history of anogenital LS. The other two cases[3,5] were in men with urostomies with no history of genital LS. One large clinical review[2] found that extragenital LS occurred without genital LS in 15% of reported cases. It may be that some of our patients with peristomal LS represent such a phenomenon; however, although the sample size is small, 9/12 (75%) had no anogenital involvement at all. In contrast to our case 10, who had a typically asymptomatic papery plaque consistent with extragenital LS, all the others had clinical features seen in severe anogenital LS, including atrophic, white plaques with associated inflammation, purpura and ulceration or erosions. The involvement was largely circumferential, reflecting the zone of occlusion and urine contact with skin, and suggesting that these aspects of the peristomal environment are at least partly responsible for the presentation. We therefore propose that peristomal LS should be regarded as a distinct form of the disease, representing in most cases a primary form more in keeping with anogenital LS than a variant of the extragenital form.

The role of occlusion in the formation of LS has been suggested in a study by Gupta *et al.*,[8] who showed that in comparison with the areas of genital skin that are typically occluded by skin folds *etc.*, the uncovered areas were not affected by LS. This theory can be extrapolated to peristomal skin that is chronically occluded by a stoma appliance. Frequent leaks onto the skin because of appliance failures usually occur because of short or buried stomas; however, continual exposure of the skin immediately adjacent to the mucocutaneous junction with urine is practically universal in patients with

Table 1 Characteristics of our patients with peristomal lichen sclerosus (LS)

Patient	Sex	Age (years)	Type of ostomy	Presence of ulceration	Presence of genital LS	Duration of ostomy (years)	Treatment	Biopsy
1	M	72	Urostomy	No	No	8	Betamethasone valerate scalp lotion and intralesional triamcinolone acetonide	Yes
2	M	76	Urostomy	Yes	No	10	Intralesional triamcinolone acetonide	Yes
3	M	78	Urostomy	Yes	No	5	Intralesional triamcinolone acetonide	Yes
4	F	47	Urostomy	Yes	Yes	3	Intralesional triamcinolone acetonide	No
5	F	77	Urostomy	No	Yes	12	Betamethasone valerate scalp lotion and intralesional triamcinolone acetonide	Yes
6	M	83	Urostomy	No	No	10	Betamethasone valerate scalp lotion	Yes
7	F	80	Urostomy	Yes	No	15	Clobetasol propionate 0·05% scalp lotion	Yes
8	F	65	Urostomy	Yes	No	3	Intralesional triamcinolone acetonide	Yes
9	F	72	Urostomy	Yes	No	2	Intralesional triamcinolone acetonide	Yes
10	F	67	Ileostomy	No	Yes	2	Betamethasone valerate cream	No
11	M	85	Urostomy	Yes	No	4	Intralesional triamcinolone acetonide	Yes
12	F	66	Urostomy	Yes	No	5	Intralesional triamcinolone acetonide and fludroxycortide-impregnated tape	Yes

M, male; F, female. All patients responded to treatment with resolution of the acute haemorrhagic inflammation and healing of the ulceration to leave typical atrophic scarring and porcelain-white sclerotic plaques. Nine patients required intralesional corticosteroids to achieve resolution. Three cases required repeated treatments over 3–6 months (cases 3, 4 and 9) and one patient suffered two relapses after successful treatment that required repeat injections of triamcinolone. Cases 4 and 5 had positive vulval biopsies for LS.

Fig 2. Lichen sclerosus. Case 10 showing a white, atrophic plaque of typical extragenital lichen sclerosus.

a urostomy, as urine is liquid and will wash back on to the stoma itself when the patient moves energetically or is recumbent. It is probably also true to say that all women and most uncircumcised men will have daily urine contact with genital skin. What is intriguing in our defined group of patients is that LS seems to be restricted to urostomies, suggesting an interplay between urine, nonadapted abdominal skin and occlusion.

We believe that the clinical presentation of peri-urostomy LS being akin to florid genital rather than extragenital LS does suggest that local factors must be involved. However, the low prevalence of the disease (12 cases in 845 new patients attending the clinic) clearly indicates that there must be factors involved other than just occlusion and the presence of urine on the skin *per se*. Studies have so far failed to identify a causative constituent in the urine that is responsible for genital LS;[9] nevertheless, we feel that our observations strongly suggest a prominent role of chronic urine contact with the skin in the formation of LS in ostomies, and the observations add to the increasing body of evidence for such a role in anogenital LS. Owen and Yell reported a series of patients who developed vulval LS following prolonged urinary incontinence.[10] In three out of seven of their patients (43%), the vulval LS cleared following control of the incontinence. Observations in male genital LS provide further evidence for the role of urine in its pathogenesis. For example, while male genital LS is exceedingly uncommon in men who are circumcised from birth,[11] it can be demonstrated histologically in almost one-third of boys with congenital phimosis.[12] Bunker *et al.*[13] have also observed that men who are chronic 'dribblers' are much more likely to develop LS.

The evidence for a combined role for occlusion and urine contact therefore seems compelling, but other factors may be involved, as demonstrated by at least one of the two cases described by Weng and Charles-Holmes as affecting colostomies.[4] This 72-year-old woman with anogenital LS also had clinical features in the peristomal skin similar to our patients with a urostomy. Studies have shown that wet skin has an increased frictional coefficient and is more likely to become eroded; furthermore, when contaminated with urine or faeces it becomes more permeable to irritants.[14] The pH of chronically wet skin rises, which in turn increases the activity of faecal enzymes causing further cutaneous or mucosal damage.[15]

For all stomas there will also be some exposure of the adjacent skin to bowel mucus, which can be an irritant. Local injury from faeces or mucus, or repeated trauma from stoma bag appliances via Koebner's phenomenon may therefore be involved in triggering the peristomal presentation of LS, at least in patients with pre-existing anogenital LS.

Genital LS is known to respond to potent topical corticosteroids in the majority of cases.[2,7] Peristomal LS tends to be painful and can be complicated by areas of ulceration, and we have found that more than half of cases require intralesional corticosteroids in order to gain disease control.

In conclusion, peristomal LS in our experience is most commonly found around urostomies, and we speculate that in addition to the possible role of local trauma and occlusion, certain – as yet unidentified – constituents in the urine possibly play a role in its aetiology.

What's already known about this topic?

- Lichen sclerosus (LS) affecting stomas has rarely been reported and has been considered a variant of extragenital LS.
- The disease is of unknown cause, but urine contact with the skin has been considered a specific aetiological factor.
- There are several other painful ulcerative conditions that can affect stomas.

What does this study add?

- A description of a large group of peristomal LS cases from a defined group of patients with stomas.
- Presentation is more commonly primary LS without genital involvement, rather than extragenital disease in patients with genital LS.
- The association with urostomies (ileal conduits) strongly indicates an association with urine exposure.

References

1 Hallopeau H. Du lichen plan et particulierement de sa forme atrophique: lichen plan sclereux. *Ann Dermatol Syphiligr* 1887; **8**:790–1.
2 Meffert JJ, Davis BM, Grimwood RE. Lichen sclerosus. *J Am Acad Dermatol* 1995; **32**:393–416; quiz 417–18.
3 Ng CS, Wolfsen HC, Kozarek RA *et al.* Chronic parastomal ulcers: spectrum of dermatoses. *J ET Nurs* 1992; **19**:85–90.
4 Weng AA, Charles-Holmes R. Peristomal lichen sclerosus affecting colostomy sites. *Br J Dermatol* 2000; **142**:177–8.
5 Farrar CW, Dowling P, Mendelsohn SD. Peristomal lichen sclerosus developing posturostomy. *Clin Exp Dermatol* 2003; **28**:223–4.
6 Funaro D. Lichen sclerosus: a review and practical approach. *Dermatol Ther* 2004; **17**:28–37.
7 Tasker GL, Wojnarowska F. Lichen sclerosus. *Clin Exp Dermatol* 2003; **28**:128–33.
8 Gupta S, Malhotra AK, Ajith C. Lichen sclerosus: role of occlusion of the genital skin in the pathogenesis. *Indian J Dermatol Venereol Leprol* 2010; **76**:56–8.
9 Edmonds EV, Bunker CB. Nuclear magnetic resonance spectroscopy of urine in male genital lichen sclerosus. *Br J Dermatol* 2010; **163**:1355–6.
10 Owen CM, Yell JA. Genital lichen sclerosus associated with incontinence. *J Obstet Gynaecol* 2002; **22**:209–10.
11 Bunker C. Diseases and disorders of the male genitalia. In: *Fitzpatrick's Dermatology in General Medicine* (Wolff K, Goldsmith L, Katz SI, Gilchrest BA, Paller AS, Leffell DJ, eds), 7th edn. New York: McGraw-Hill, 2007; 852–78.
12 Mattioli G, Repetto P, Carlini C *et al.* Lichen sclerosus et atrophicus in children with phimosis and hypospadias. *Pediatr Surg Int* 2002; **18**:273–5.
13 Bunker CB, Edmonds E, Hawkins D *et al.* Re: Lichen sclerosus: review of the literature and current recommendations for management: J. M. Pugliese, A. F. Morey and A. C. Peterson J Urol 2007; 178: 2268–2276. *J Urol* 2009; **181**:1502–3.
14 Faria DT, Shwayder T, Krull EA. Perineal skin injury: extrinsic environmental risk factors. *Ostomy Wound Manage* 1996; **4**:36–7.
15 Gray M. Incontinence-related skin damage: essential knowledge. *Ostomy Wound Manage* 2007; **53**:28–32.